

Instruments and Techniques

CO₂ Laser Total Superficial Vulvectomy: An Outpatient Treatment for Wide Multifocal Vulvar Intraepithelial Neoplasia Grade 3

Maria Grazia Fallani, MD, Massimiliano Fambrini, MD*, Virginia Lozza, MD, Claudia Bianchi, MD, and Annalisa Pieralli, MD

From the Department of Science for Woman and Child Health, University of Florence, Florence, Italy (all authors).

ABSTRACT The ideal treatment of large multifocal vulvar intraepithelial neoplasia grade 3 (VIN 3) in young patients is still debated. The goal is to prevent development of invasive vulvar cancer while preserving normal vulvar anatomy and function. The authors describe the case of a 37-year-old woman affected by a biopsy-proven VIN 3 involving the entire external genitalia. A total superficial vulvectomy was carried out in 2 closer sessions by CO₂ laser used in an excisional way. Both procedures were performed in an outpatient setting with the patient under local anesthesia and without suturing stitches or skin flaps. Definitive pathologic analysis confirmed VIN 3 with free margins. No intraoperative and postoperative complications were documented. Functional and anatomic outcomes were optimal, and no relapse occurred after 12 months of follow-up. Use of CO₂ laser total superficial vulvectomy shows promise of a safe and adequate treatment in selected young patients with VIN 3 involving the entire external genitalia. *Journal of Minimally Invasive Gynecology* (2012) 19, 758–761 © 2012 AAGL. All rights reserved.

Keywords: VIN 3; Vulvectomy; CO₂ laser

DISCUSS You can discuss this article with its authors and with other AAGL members at <http://www.AAGL.org/jmig-19-6-12-00301>



Use your Smartphone to scan this QR code and connect to the discussion forum for this article now*

* Download a free QR Code scanner by searching for "QR scanner" in your smartphone's app store or app marketplace.

Vulvar intraepithelial neoplasia grade 3 (VIN 3) is believed to be a precursor of vulvar squamous cell cancer, and its frequency appears to have been increasing during the past 2 decades [1,2]. Given the increase of younger age of patients with this disease, a gradual trend toward conservatism in the management of VIN lesions developed. At present subjecting young women to classic surgical disfiguring treatments can no longer be justified; for this reason some alternatives to classical surgical excision or vulvectomy have been developed such as CO₂ laser vaporization [3,4], topical imiquimod [5], and photodynamic therapy [6]. However, vulvar-conserving treatments have similar limited success rates, especially when facing widespread multifocal diseases; thus the high recurrence rate

together with the risk of unrecognized invasive disease are the main challenges with these methods [7,8]. In this report we describe a novel surgical technique that allows us to treat widespread multifocal VIN 3 in an outpatient setting with local anesthesia by the use of CO₂ laser.

Case

A 37-year-old healthy white woman with a history of smoking, who previously underwent cervical cone biopsy for cervical intraepithelial neoplasia grade 3, was referred to our institution complaining of vulvar itching. Clinical examination revealed a flat erythematous zone mixed with a thickened, hyperkeratotic, and granular white epithelium and some raised warty lesions extending over the larger part of the vulva including the labia minora and majora of both sides, the clitoris, periurethral area, and perineum (Fig. 1A). Multiple punch biopsy specimens were obtained on the sites of major macroscopic atypia and at the periphery of the area of vulvar involvement and with a histological diagnosis of bowenoid VIN 3 in all the specimens.

The authors declare that they have no conflict of interest.

Corresponding author: Massimiliano Fambrini, MD, Department of Science for Woman and Child Health, University of Florence, Viale Morgagni, 85, 50134, Florence, Italy.

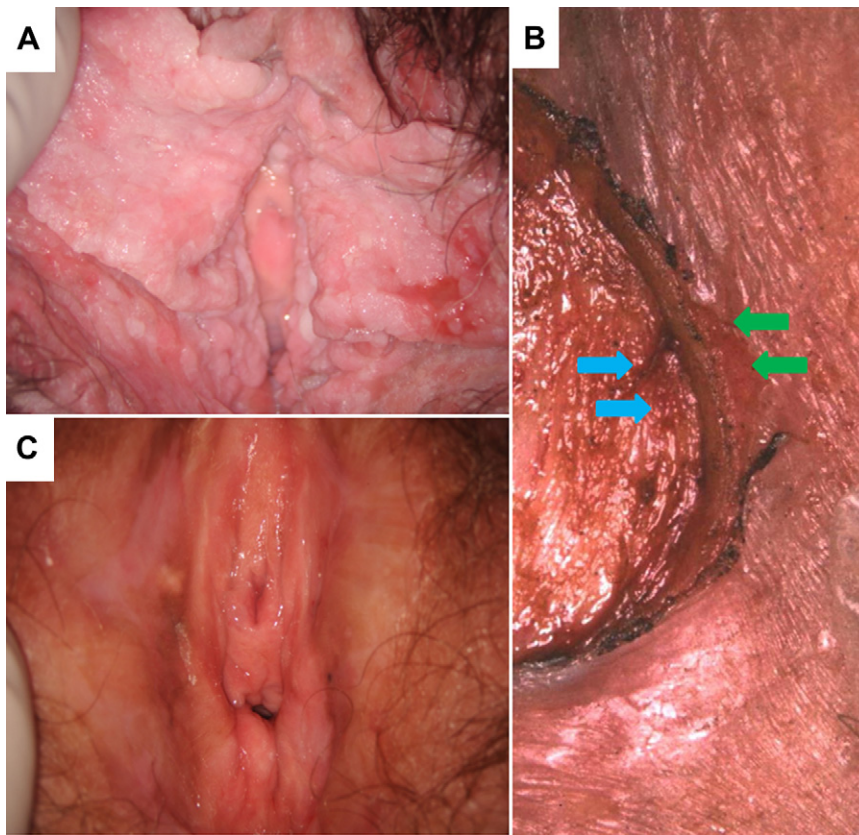
E-mail: maxfambrini@libero.it

Submitted June 18, 2012. Accepted for publication August 2, 2012.

Available at www.sciencedirect.com and www.jmig.org

Fig. 1

Vulvar macroscopic aspect before treatment (A); Colposcopic detail of the excision border during laser superficial vulvectomy shows normal epithelium (green arrows) and mid reticular dermis (blue arrows) separated by a 2.5- to 3-mm-deep excision (B). Follow-up visit 6 months after treatment (C).



Because of the wide superficial spread of the biopsy-proven high-grade disease comprising all the external genitalia from the clitoris to the perianal area, we planned left and right partial superficial vulvectomy by CO₂ laser, which was used as excisional tool in 2 different sessions, obtaining the patient's informed consent for the planned procedure.

The instrument was a CO₂ laser (DEKA M.E.L.A. SRL, Calenzano, Florence, Italy) at 20 watts, used in a continuous mode, connected to a Zeiss OPMI colposcope (Carl Zeiss, Oberkochen, Germany), with a beam-spot diameter of 2 mm and guided by a micromanipulator. The laser procedure was performed in an outpatient setting by an expert laser surgeon and 2 helpers; patients were under local anesthesia. Multiple 27-gauge needle injections of a 2% lidocaine mixed with epinephrine 1:100 000 were performed.

During the first session the involved area and a wide margin of grossly normal-appearing skin of the left hemivulva and perineal area was dissected entirely to a depth of 2.5–3 mm (Fig. 1B), pulling it with a hook from the underlying mid dermal healthy tissue. The surgeon's colposcopic magnification allowed maintenance of a uniform depth throughout the specimen during the excision. The clitoris was scraped off its prepuce to a depth closer to 2 mm, conserving its body. In

agreement with the patient, we decided to remove the left labia minora because it was affected by disease on both sides and was at high risk of necrosis in the early postoperative period. No skin graft or suture of the margins of the surgical defect was performed. Two weeks after the first procedure, the right side of the vulva and the perineum were treated with the same procedure, and, in agreement with the patient, the right labia minora was removed as well.

No major bleeding (enough to stop the treatment) occurred during either of the procedures, which lasted 21 minutes and 17 minutes, respectively. During both procedures the patient was asked to evaluate subjective pain through a visual analogue scale (VAS); she scored it as much as 2 in the second part of the first procedure. After surgery cotton balls soaked in an antibiotic solution (Rifamycin 90 mg solution for intralesional and cutaneous use) were applied on the vulvar skin defect and secured with sticky bands for 24 hours.

The patient was discharged 1 hour after the end of the procedures with the request to remove the applied medication the day after, to take oral antibiotics for 6 days (amoxicillin 875 mg plus clavulanic acid 125 mg, twice/daily), and to clean and moisten the wound 3 times daily with an anesthetic lubricant pomade (lidocaine hydrochloride 2.5 g) until

healing was complete. The patient received a VAS for scoring subjective pain from a minimum of 1 to a maximum of 10 during the healing process and an index of female sexual function questionnaire to assess sexual dysfunction [9].

Definitive histologic analysis of excised specimens confirmed bowenoid VIN 3 and all surgical margins to be clear of the disease. Macroscopic measurement of gross specimens confirmed a depth of excision of 2.5–3 mm.

The patient was checked once weekly, and complete healing of the skin defect occurred after 3 weeks in both sites of the vulvar region. At the VAS recorded during the healing process, the patient scored subjective pain as 5, mostly burning, easily controlled by repeating the moistening medication and taking low-dose pain-relief drugs such as oral acetaminophen 1000 mg or ibuprofen 400 mg twice/daily.

Six-month evaluation revealed an excellent cosmetic result apart from missing labia minora (Fig. 1C). No scarring appeared on the vulvar surface, and no contraction of the introitus was noticed. The patient's index of female sexual function was 5, indicating that no sexual dysfunction occurred after the procedure. She didn't complain of disruption of self-image. No relapse of the disease was observed at 12 months.

Discussion

VIN 3 is believed to be a precursor of squamous cell vulvar cancer, and for this reason it requires active management. Furthermore, with increased incidence of this disease among young women, not only can prevention of invasive disease be considered a primary endpoint, but also the preservation of normal anatomy and function [1]. There is little consensus on the optimal management of VIN 3, mostly because of the unknown potential of progression of the bowenoid histotype but also the possibility of local spreading and common relapse [7,8].

CO₂ laser vaporization has already been tested [3,10] as a treatment option for VIN and is considered part of the class of conservative treatments, along with photodynamic therapy [6] and topical use of immune modulators [5]. Functional and cosmetic results were optimal with such approaches; however, a recurrence rate ranging from 10% to 48% has not led to consideration of these techniques as the preferred solution [5–8,10].

Another point of utmost importance in the choice of treatment when facing a wide spread biopsy-proven VIN 3 is the risk of overlooking an early stromal invasion. Pretreatment biopsy fails to reveal the presence of invasive disease subsequently found in definitive analysis of specimens in 4%–12% of patients [11]; for this reason the removal of tissue for definitive histologic analysis should be the mainstay of treatment, especially in large and multifocal disease.

In a recent analysis comparing CO₂ laser vaporization, photodynamic therapy, wide excision, and classical surgical vulvectomy [8], the latter was described as the only method

able to reduce the recurrence rate to zero, providing a post-surgical definitive histologic study. Therefore, from an oncologic point of view, it seems to be the ideal treatment, being nevertheless a major surgical procedure with destructive effects on the anatomy of the genital area, resulting in disruption of sexual activity and body self-image. For these reasons classical surgical vulvectomy is today considered an unacceptable option for young patients with intraepithelial disease even if it is widespread and multifocal.

Realizing that the disease may affect only the epithelium, some authors in the 1980s proposed the so-called “skinning vulvectomy,” where vulvar skin was surgically removed without disturbing the subcutaneous fatty tissue [12,13]. This procedure was associated with a high cure rate and low recurrence rate in subsequent follow-up. Moreover, it produced acceptable cosmetic results by the use of split-thickness skin grafting from the thigh to cover the loss of tissue caused by excision. Nevertheless the procedure was performed with the patient under general anesthesia and required suturing, catheterization, and long-term healing. Surgical complications included blood loss, dysuria, abnormal discharge, and infection of the sutures. For these reasons, although it has represented an important step from theoretical and technical viewpoints, surgical skinning vulvectomy with skin grafting for vulvar intraepithelial disease was abandoned.

In a previous series [4], and in accord with other authors [3], we described the excisional use of CO₂ laser for the treatment of VIN in an outpatient regimen with local anesthetic with excellent cosmetic and functional results. In experienced hands it combines the advantages of classical surgical excision in relation to cure rate and correct diagnosis and the advantages of laser vaporization with respect to cosmetic and functional results, and it appears to be the elective treatment modality for VIN 3.

The lack of scarring observed with CO₂ laser excisional treatment is the result of combining colposcopic guidance and the use of a micromanipulator to direct the laser beam. In this way a controlled dissection of the skin surface can be performed, with skin excision accurately calibrated to a depth of 2.5–3 mm able to remove entirely the epithelial layer and papillary dermis while preserving midreticular dermal tissue. Considering this aspect we previously analyzed the problem of using laser excision in hair-bearing areas where there may be extension of VIN into the underlying skin appendages [4]. The combined rate for pilosebaceous-unit involvement ranges in the literature from 11.5% to 53% [14–16], but in the vast majority of the studies the mean depth of appendage involvement did not exceed 2 mm [14–17]. For this reason the excision of the hairy skin to a depth of 2.5–3 mm should effectively eliminate all atypical epithelium in skin appendages, avoiding the scarring process during postoperative healing.

This is the first report describing a total superficial vulvectomy performed by CO₂ laser in 2 outpatient sessions. Even if the treatment includes the entire vulvar area, the observed

findings confirm the advantages offered by CO₂ laser as previously reported with vulvar local excision [3,4]. With the CO₂ laser connected to a micromanipulator, under colposcopic guidance the tissue excision can be held at the required depth in all vulvar areas. Moreover, because of the high precision of the technique, surgical excision can be tailored, preserving healthy tissue in areas where classical surgical approach would be difficult, such as in perianal, periurethral, and periclitoral regions. Long-term follow-up confirmed the optimal cosmetic and functional outcomes.

With regard to the oncologic aspect, this procedure provides the opportunity to excise wide surgical margins and furnishes adequate specimens for pathologic assessment. No recurrences were observed during the first year of follow-up.

Technically speaking, the treatment was performed in 2 closer sessions to reduce early postoperative pain and allow for easier cleaning and disinfection. The ability to perform the 2 procedures in a short time frame without delaying the therapy is mainly due to the outpatient setting and use of local anesthesia. No other excisional treatment that is able to remove most of the vulvar surface can be rapidly performed in the outpatient setting with the patient under local anesthesia, and this is principally due to 2 intrinsic features of CO₂ laser.

First, it helps in controlling subjective intraoperative and postoperative pain through its specific capability to destroy nerve endings, preventing raw ends that are characteristic of scalpel blades. Second, it obviates the need for hemostats or added coagulating procedures to take care of oozing blood vessels throughout the surgery, because it is itself a highly effective coagulator of small vessels.

In conclusion, we are aware this is only the report of a case, and further work needs to be done to determine whether the technique is appropriate in a larger population of typical VIN. Nevertheless, this case suggests that in selected young patients with large VIN 3 involving the entire external genitalia, CO₂ laser vulvectomy may represent an effective therapeutic option because it provides adequate oncologic management with excellent cosmetic results. However, because of the low prevalence of these cases, they should be referred to experienced centers where procedures can be properly performed by skilled laser surgeons.

Acknowledgments

We thank DEKA M.E.L.A. SRL for the technical support.

References

- Judson PL, Habermann EB, Baxter NN, Durham SB, Virnig BA. Trends in the incidence of invasive and in situ vulvar carcinoma. *Obstet Gynecol.* 2006;107:1018–1022.
- Lanneau GS, Argenta PA, Lanneau MS, et al. Vulvar cancer in young women: demographic features and outcome evaluation. *Am J Obstet Gynecol.* 2009;200:645.e1–645.e5.
- Sideri M, Spinaci L, Spolti N, Schettino F. Evaluation of CO(2) laser excision or vaporization for the treatment of vulvar intraepithelial neoplasia. *Gynecol Oncol.* 1999;75:277–281.
- Penna C, Fallani MG, Fambrini M, Zipoli E, Marchionni M. CO2 laser surgery for vulvar intraepithelial neoplasia. Excisional, destructive and combined techniques. *J Reprod Med.* 2002;47:913–918.
- Terlou A, van Seters M, Ewing PC, et al. Treatment of vulvar intraepithelial neoplasia with topical imiquimod: seven years median follow-up of a randomized clinical trial. *Gynecol Oncol.* 2011;121:157–162.
- Hillemanns P, Untch M, Dannecker C, et al. Photodynamic therapy of vulvar intraepithelial neoplasia using 5-aminolevulinic acid. *Int J Cancer.* 2000;85:649–653.
- von Gruenigen VE, Gibbons HE, Gibbins K, Jenison EL, Hopkins MP. Surgical treatments for vulvar and vaginal dysplasia: a randomized controlled trial. *Obstet Gynecol.* 2007;109:942–947.
- Hillemanns P, Wang X, Staehle S, Michels W, Dannecker C. Evaluation of different treatment modalities for vulvar intraepithelial neoplasia (VIN): CO(2) laser vaporization, photodynamic therapy, excision and vulvectomy. *Gynecol Oncol.* 2006;100:271–275.
- Rosen R, Brown C, Heiman J, et al. The Female Sexual Function Index (FSFI): a multidimensional self-report instrument for the assessment of female sexual function. *J Sex Marital Ther.* 2000;26:191–208.
- Ferenczy A, Wright TC, Richart RM. Comparison of CO2 laser surgery and loop electrosurgical excision/fulguration procedure (LEEP) for the treatment of vulvar intraepithelial neoplasia (VIN). *Int J Gynecol Cancer.* 1994;4:22–28.
- Polterauer S, Catharina Dressler A, Grimm C, et al. Accuracy of preoperative vulva biopsy and the outcome of surgery in vulvar intraepithelial neoplasia 2 and 3. *Int J Gynecol Pathol.* 2009;28:559–562.
- Caglar H, Delgado G, Hreshchyshyn MM. Partial and total skinning vulvectomy in treatment of carcinoma in situ of the vulva. *Obstet Gynecol.* 1986;68:504–507.
- Rettenmaier MA, Berman ML, DiSaia PJ. Skinning vulvectomy for the treatment of multifocal vulvar intraepithelial neoplasia. *Obstet Gynecol.* 1987;69:247–250.
- Benedet JL, Wilson PS, Matisic J. Epidermal thickness and skin appendage involvement in vulvar intraepithelial neoplasia. *J Reprod Med.* 1991;36:608–612.
- Baggish MS, Sze EH, Adelson MD, Cohn G, Oates RP. Quantitative evaluation of the skin and accessory appendages in vulvar carcinoma in situ. *Obstet Gynecol.* 1989;74:169–174.
- Shatz P, Bergeron C, Wilkinson EJ, Arseneau J, Ferenczy A. Vulvar intraepithelial neoplasia and skin appendage involvement. *Obstet Gynecol.* 1989;74:769–774.
- Mene A, Buckley CH. Involvement of the vulval skin appendages by intraepithelial neoplasia. *Br J Obstet Gynaecol.* 1985;92:634–638.